

## Original

# Clinical Investigation of Dental Implant Reconstruction for Grafted Alveolar Cleft Patients

Masako Sawaki<sup>1)</sup>, Takaaki Ueno<sup>1,2)</sup>, Toshimasa Kagawa<sup>1,2)</sup>, Nobuyoshi Mizukawa<sup>1,2)</sup>, Miwa Kanou<sup>1,2)</sup>, Yoshiro Sakata<sup>1)</sup>,  
Kozo Honda<sup>1,2)</sup>, Nobuaki Shirasu<sup>1)</sup> and Toshio Sugahara<sup>1,2)</sup>

<sup>1)</sup>Department of Oral and Maxillofacial Reconstructive Surgery, Okayama University Graduate School of Medicine, Dentistry and Pharmaceutical Sciences, 2-5-1, Shikata, Okayama, Japan, 700-8558

<sup>2)</sup>Clinic of Oral Implantology, Okayama University Hospital, 2-5-1, Shikata, Okayama, Japan, 700-8558

(Accepted for publication, May 28, 2007)

**Abstract:** The purpose of this study was to evaluate the clinical application of endosseous implants for management of grafted alveolar cleft.

Four patients (1 male and 3 female; mean age 26.6 years; age ranging from 21.5 to 30.4 years at first implant surgery) with unilateral cleft lip and palate were evaluated. All patients received autogenous particulate cancellous bone and marrow graft (PCBM) to close the alveolar cleft. After bone bridge formation, implant treatment was performed. All patients with insufficient alveolar bone height, chin or ramus of mandible bone, onlay grafting was performed 4 months before implant installment.

A total of 5 implants were placed in the grafted alveoli. The length of implants ranged from 10.0 to 13.0 mm. The follow-up period ranged from 2.2 to 4.1 years after implant placement. The clinical result was acceptable in all patients. The survival rate of implants was 100%.

Implant treatment for grafted alveolar cleft was studied and the outcome of treatment was acceptable.

**Key Words:** Dental implant, Cleft lip and palate, Dental reconstruction

## Introduction

Dental rehabilitation of patients with alveolar cleft is the most challenging. Secondary bone grafting in alveolar clefts is a well-established procedure performed to close the oronasal fistula, allowing the teeth to erupt in the cleft lesion, provide bony support to the teeth adjacent to the cleft, stabilize the premaxillary segment of bilateral cases and create support for the alar base.

After bone grafting in the alveolar cleft, conventional prostheses such as removable partial endosseous dentures or dental bridges are used for dental reconstruction in such cases. Recently, some researchers reported the efficacy of dental implant after the repair of alveolar clefts with secondary bone grafting<sup>1-4)</sup>. However, few reports have examined the efficacy of dental implants in the grafted alveolar cleft. The aim of the present study is to examine the clinical efficacy of dental implants for grafted alveolar cleft.

## Patients and methods

### Patients

Correspondence to: Masako Sawaki, DDS., Ph.D., Department of Oral and Maxillofacial Reconstructive Surgery, Okayama University Graduate School of Medicine, Dentistry and Pharmaceutical Sciences, Okayama 700-8558, Japan. Phone: +81-86-235-6697. Fax: +81-86-235-6699. Email: gmd17129@cc.okayama-u.ac.jp

Four patients (1 male and 3 female) with alveolar cleft received dental implant treatment at the Department of Oral and Maxillofacial Reconstructive Surgery, Okayama University Medical and Dental Hospital. The distribution of patients is listed in Table. 1. All of the patients had unilateral cleft lip and palate. The mean age at first implant surgery was  $26.6 \pm 3.9$  years (range 21.5 to 30.4). Preoperative systemic examination revealed no significant health problems in any of the patients.

### Methods

#### (1) Bone grafting

All patients had received autogenous particulate cancellous and bone marrow (PCBM) graft from the ilium between 16.6 and 27.9 years of age (mean age,  $22.1 \pm 5.2$ ).

#### (2) Evaluation of grafted bone

Preoperative evaluation of the bone bridges was performed with computed tomography (CT) and periapical radiographs. Interdental alveolar bone height was evaluated as was previously reported by Takahashi et al.<sup>5)</sup> Fig. 1

#### (3) Implant procedure

Three of the patients received autogenous bone from the mandibular chin bone onlay grafting (CBOG) to achieve sufficient

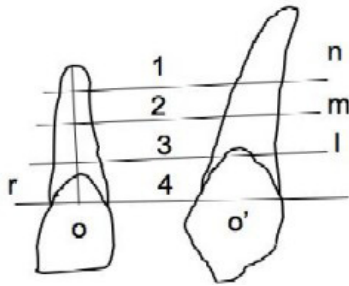


Figure 1: Evaluation of interdental alveolar bone height based on radiograph and scoring parameter.

The numbers of score is determined as followed: Score 4: Bone height was positioned between l and r, Score 3: Bone height was positioned between m and l. Score 2: Bone height was positioned between n and m. Score 1: Bone height was positioned below n.

height of alveolar bone 4 months before implant installment. A total of 5 Branemark System implants (Nobel Biocare, Japan, Tokyo) were placed based on the bone volume of the treated bone (Table 2). Six months after implant placement, appropriate abutments (Nobel Biocare, Japan, Tokyo) were connected. Subsequently, a freestanding superstructure was used in all patients. Fig.2A-D

### Results

A total of 5 implants were placed in the grafted alveolar clefts in the 4 patients (Table1, 2). Three implants were installed in the lateral incisor region. One implant was placed in the central incisor region and one in the canine region. Three patients received CBOG 4 months prior to implant installment. All bone grafting procedures were successful. In one case (case 2), simultaneous implant installment was combined with CBOG, the grafted bone severely resorbed after implant installment surgery and the labial side threads of the implant were slightly exposed. But the implant was stable.

The implant length ranged from 10 mm to 13 mm. The most frequently used implant length was 11.5mm. The duration from bone grafting to first implant surgery ranged from 1 to 11.4 years (mean 4.5 years).Table 1

The follow-up period after implant surgery ranged from 2.2 to 4.1 years (mean period 3.2 years). The clinical outcome was good in all cases and the patients were satisfied. All implants survived during the period of this short-term observation (5/5).

### Discussion

In the present study, we investigated the clinical application of dental reconstruction with endosseous implants in patients with grafted alveolar clefts. Although many reports have demonstrated excellent results with dental implants histologically, radiographically and clinically<sup>6-8)</sup>, few studies have examined the results of implant treatment in cleft lip and palate patients.

The use of commercial pure titanium implanted into maxilla and mandible facilitates direct bone apposition to the implant surface creating a unique bone-implant interface, which is termed osseointegration<sup>9-10)</sup>. The ability of titanium to achieve firm anchorage in bone without an intervening soft tissue layer is required for implant stability and longevity. Previous implant materials failed to match this quality<sup>9)</sup>. It is the intimate relationship between host bone and the titanium implant surface that is responsible for the implant success rate. On the other hand, the alveolar ridge of cleft patients is usually reconstructed with PCBM. The surface of implants installed in grafted alveolar cleft contacts the bony bridge in the cleft formed from grafted bone, which may sometimes include chin bone onlay or ramus bone additionally grafted to recover the insufficient height.

In this study, all patients had received PCBM graft from ilium to close the alveolar cleft prior to implant treatment. But 3 of the 4 patients required additional bone grafting to increase the alveolar height. We used mandibular chin bone to augment the alveolar height of the bony bridge of the alveolar cleft. This intraoral bone harvesting technique has been shown to be very acceptable for the treatment of patients with alveolar ridge atrophy resulting from trauma, tumor resection and periodontal disease. Raghoever et al.<sup>11)</sup> reported a high success rate of 92% for dental implants with chin bone grafting. Jensen et al.<sup>12)</sup> also reported a success rate of 95% for dental implants with autogenous bone graft harvested from the mandibular ramus. However, the efficacy of dental

Table 1: Demographic and clinical characteristics of the subjects.

Patient No.	Sex	Age at Bone Grafting (yr)	Age at First Implant surgery(yr)	Dulation of Bone Formation (yr)	Fixture Length (mm)	Follow-up Period (yr)	Comments	Bone Quantity Score Fig.1
1	F	27.9	8.9	1	11.5	3.6		1
2	F	19	30.4	11.4	13	4.1	CBOG, Bone resorption	2
3	M	16.6	21.5	4.9	11.5	3.2	CBOG	3
4	F	24.9	25.9	1	10	2.2	CBOG	2
Mean		22.1	26.6	4.5		3.2		
SD		5.2	3.9	4.9		0.8		
Range		16.6-27.9	21.5-30.4	1-11.4	10-13	2.2-4.1		

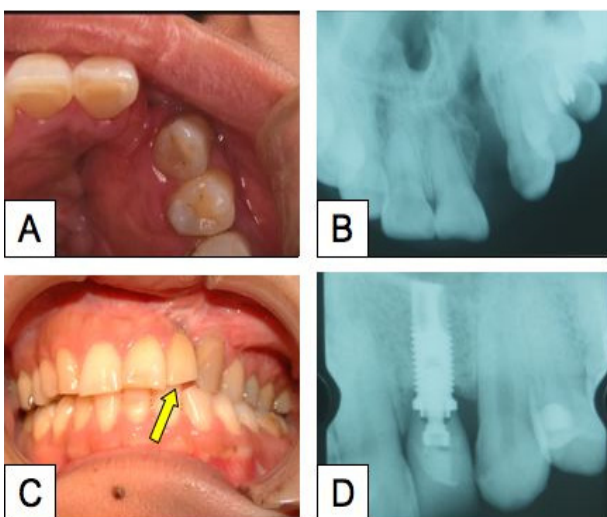


Fig. 2: Pictures of patient case 1. A: Note missing left lateral incisor tooth during the first visit. B: Radiograph of alveolar cleft. C: Intraoral view of 2 years after final prosthesis supported by endosseous implant. D: Radiograph of follow-up period.

implants with intraoral bone graft for cleft alveolaris after grafting with iliac PCBM has not been well investigated. The most difficult part of dental implant treatment in cleft lip and palate patients who have received multiple operations for cleft repair is the soft tissue management after chin bone onlay grafting. This is because the soft tissue has become too fibrous making difficult to close the bone augmented alveolaris graft. Therefore, dehiscence occurs easily after CBOG or ramus bone onlay grafting (RBOG). Takahashi et al.<sup>5)</sup> also described exposure of CBOG 2 weeks after surgery and failure of implant treatment. We also observed exposure of the grafted bone and resorption of the CBOG in case 2. These failures could be due to the simultaneous implant placement with bone grafting. The soft tissue was not adequate to cover the implant head and grafted onlay bone. The other 2 cases underwent implant surgery 4 months after CBOG and showed good prognosis in the observation period. We do not recommend the simultaneous implant placement with bone grafting.

The installed implants showed acceptable osseointegration without bone resorption after connecting the superstructure except case 2. Clinically, there were no problems in the other teeth and alveolar process. It was reported by Takahashi et al.<sup>5)</sup> that within 19 cleft lip and palate (CLP) patients, half of them required CBOG to increase the alveolar bone height for placement of dental implants of adequate length. In our study also, 3 of the 4 patients required CBOG to increase alveolar height. On the other hand, Buser et al.<sup>13)</sup> reported the efficacy of guided bone regeneration technique with a resorbable or non-resorbable membrane for atrophied alveolar ridge. Zaffe et al.<sup>14)</sup> suggested callus distraction to increase bone height without bone grafting. We believe that the combination of these options with autogenous bone grafting might bring more satisfactory results in future.

We evaluated the clinical outcome of endosseous implants

Table 2: Distribution of installed implant length and location

Implant Length (mm)	Location of Implants		
	Incisor		
	Center	Lateral	Cannine
7			
10		1	
11.5		2	
13	1		1
	1	3	1

installed in the alveolar cleft repaired with autogenous PCBM graft. Our results suggest the efficacy of dental treatment in patients who underwent treatment of CLP repair with PCBM. Moreover, this treatment permits an acceptable esthetic outcome without the necessity of removable denture or bridge.

**References**

- Verdi FJ, Landi GL and Cohen SR: Use of the Branemark implant in the cleft palate patients. *Cleft palate J* 28:301-303, 1991
- Ronchi P and Frattini CD: Endossous implants for prosthetic rehabilitation in bone grafted alveolar cleft. *J Craniomaxillofac Surg* 23:382-386, 1995
- Deppe H, Horch HH and Kolk A: Microstructured dental implants and palatal mucosal graft in cleft patients: a retrospective analysis. *J Cranimaxillofac Surg.* 32:211-215, 2004
- Cune MS, Meijer GJ and Koole R: Anterior tooth replacement with implants in grafted alveolar cleft site: a case series. *Clin Oral Impl Res* 15:616-624, 2004
- Takahashi T, Fukuda M, Yamaguchi T and Kochi S: Use of endosseous implants for dental reconstruction of patients with grafted alveolar cleft. *J Oral Maxillofac Surg* 55:576-583, 1997
- Adell O, Leckholm U, Rocker B and Branemark PI: A 15 year study of osseointegration implants in the treatment of the edentulous jaw. *International surgery of Oral Surgery* 10 :387-416,1981
- Ewers R: Maxilla sinus grafting with marine aglae derived bone forming material: a clinical report of long-term results. *J Oral Maxillofac Surg.* 63(12):1712-23, 2005
- Branemark PI, Breine U, Adell R, Hansson BO, Lindstrom J and Ohlsson A: Intraosseous anchorage of dental prostheses. Experimental studies. *Scandinavian Journal of Plastic & Reconstructive Surgery* 3:81-100, 1969
- Branemark PI, Lindstrom J, Hallen O, Breine U, Jeppson PH and Ohman A: Reconstruction of the defective mandible. *Scandinavian journal of plastic and reconstructive surgery* 9:116-121, 1975

10. Klokkevold PR, Nishimura RD, Adachi M and Caputo A: Osseointegration enhanced by chemical etching of the titanium surface. *Clin Oral Impl Res* 8:442-447, 1997
11. Raghoobar GM, Brauwer J, Reintsema H and Van Oort RP: Augmentation of the maxillary sinus floor with autogeneous bone for the placement of endosseous implants: A preliminary report. *J Oral Maxillofac Surg* 51:1198-1203, 1993
12. Jensen J and Sindet-Pederson S: Autogeneous mandibular bone grafts and osseointegrated implants for reconstruction of the severely atrophied maxilla: A Preliminary Report. *J Oral Maxillofac Surg* 49:1277-1287, 1991
13. Buser D, Bragger U and Lang NP: Regeneration and enlargement of jaw bone using guided tissue regeneration. *Clin Oral Implant Res* 1:22-32, 1990
14. Zaffe D, Bertoldi C, Palumbo C and Consolo U: Morphofunctional and clinical study on mandibular alveolar distraction osteogenesis. *Clin Oral Impl Res* 13:550-557, 2002