

## Original

# Dental Pulp Changes Observed in a Patient on Long-term Corticosteroids

Yoshiho Chigono<sup>1)</sup>, Tateo Daimon<sup>2)</sup>, Makoto Miyagawa<sup>3)</sup>, Yasushi Miake<sup>4)</sup>, Mitsuko Moriguchi<sup>4)</sup>,  
Yoko Tanabe<sup>1)</sup>, Yoshihiro Takeyasu<sup>1)</sup> and Yoshimi Ichinokawa<sup>1)</sup>

1)Department of Maxillo-facial Surgery, School of Medicine, Teikyo University

2)Department of Anatomy, School of Medicine, Teikyo University

3)Animal Center, School of Medicine, Teikyo University

4)Department of Ultrastructural Science, Tokyo Dental College

(Accepted for publication, January 10, 2007)

**Abstract:** We encountered a patient on long-term oral corticosteroids for systemic lupus erythematosus, who did not complain of pain during caries treatment. Since the patient had no subjective sense of dental pain, all her remaining teeth became stumps, and total tooth extraction was conducted 25 years after presentation. We examined her premolar stumps histopathologically and obtained the following findings: 1. the dental pulp was narrowed in nearly all samples; 2. odontoblasts were not observable; 3. regions with dentinal tubules forming lamellae and regions with fibrotic dentinal tubules were observed. 4. fibrosis of the entire dentin was observed in some regions. 5. nerve fibers stained by anti-neurofilament protein antibody were observed in the dental pulp cavity, but the nerve fibers appeared degenerate and no nerve fiber endings were observed.

**Key words:** Corticosteroids, Narrowing of dental pulp cavity, Odontoblast, Immunohistochemical staining of nerve fibers, Silver staining

### Introduction

Narrowing of the dental pulp cavity is not a rare dental pulp change observed clinically<sup>1,2)</sup>, and dental pulp changes have been observed in patients on long-term chronic treatment with corticosteroids (PL). In 1963, Anneroth et al<sup>3)</sup> reported the observation of pulp calcification in the incisors of cortisone-pretreated rats. In 1996, Näsström<sup>4)</sup> reviewed the status of renal transplant patients on PL. Subsequently a few clinical reports on narrowing of the dental pulp cavity have been published<sup>5-7)</sup>.

We encountered a patient on long-term oral PL for systemic lupus erythematosus, who did not complain of pain during caries treatment. Because the patient had no subjective sense of pain, all her remaining teeth became stumps, and total tooth extraction was conducted 25 years after presentation. Since we were able to follow the dental pulp changes in the patient on long-term PL, we examined the relationship between lack of tooth pain and dental pulp changes by conducting various staining of the dental pulp.

### Case Presentation

A 25 year-old woman presented at the dental department of Teikyo University in 1979 for cavity treatment. She was diagnosed of rheumatoid arthritis (RA) at the later half of age 10, and started

to take oral PL. At presentation, she had continued to take PL under a diagnosis of SLE. She could not remember the exact time of starting oral corticosteroid except that it was at the later half of age 10.

At presentation (25 years of age), she was found to have one tooth stump. Tooth extraction was conducted and a partial denture was constructed. Figure 1 shows the radiograph at presentation. The dental pulp was narrowed in the anterior teeth, while the dental pulp was visible in the molars.

In 1981 (27 years of age), she revisited our department for treatment of cavities in the central incisors. There was no pain even when grinding the 11 cavities. The cavities were filled (Figure 2).

In 1984 (30 years of age), she revisited for a cavity in 2. The dental root with dental pulp was removed without pain (Figure 3).

In 2003 (50 years of age), she revisited with only stumps remaining in multiple teeth, because she did not seek dental care due to a lack of pain. Since she had declined feeding function, the teeth were extracted for denture construction. Full dentures were worn for upper and lower jaws. The teeth extracted were used as materials for further studies (Figure 4). Radiographs were taken after tooth extraction (11 1 2 3 4). In the stumps, the dental pulp was either filament-like or invisible.

In 2006 (53 years of age), she was suspected of dermatomyositis, and has continued to take oral PL to date.

Corresponding author: Yoshiho Chigono, Department of Maxilla-facial Surgery, School of Medicine, Teikyo University, 2-11-1 Kaga, Itabashi-ku, Tokyo 173-8605, Tel: 03-3964-1211, E-mail: chigono@med.teikyo-u.ac.jp

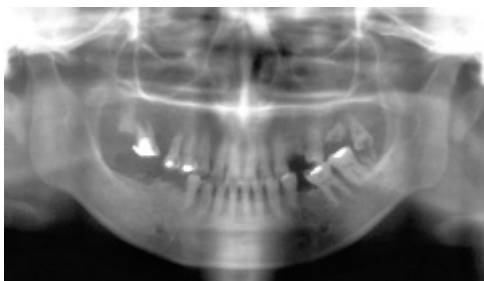


Figure 1. Radiograph taken at presentation (25 years of age). The dental pulp cavity is difficult to see in the anterior teeth, and is narrowed to a thread-like shape in the premolars. The dental pulp cavity is clearly visible in the molars.

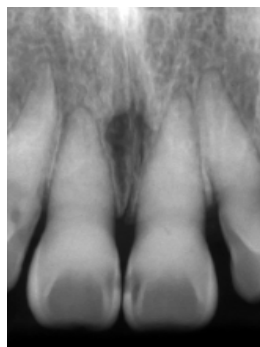


Figure 2. Radiograph at 27 years of age. The dental pulp cavity is almost invisible in 11.

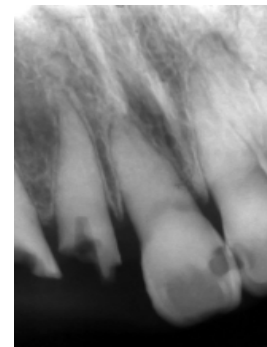

Figure 3. Radiograph after dental root and dental pulp treatment at 30 years of age. The dental pulp is invisible in 21.

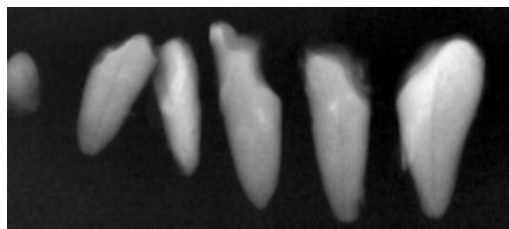


Figure 4. Radiograph after tooth extraction at 50 years of age. Stumps with no identifiable dental pulp and stumps with thread-like dental pulp are observed.

From the later half of age 10 to date, the patient has taken oral PL almost continuously for 40 years with little interruption, although there were dose increases and reductions.

## Materials and Methods

### Specimen preparation

Premolars extracted from the patient on long-term oral PL were studied. As control, molars obtained from normal human adults by tooth extraction were used. The premolars and molars were fixed by immersing in 20% neutral buffered formalin for 1 to 3 days. After rinsing slightly in water, the teeth were decalcified in 10% EDTA at room temperature for 5 to 6 weeks. Thereafter, paraffin embedded blocks were prepared by the conventional methods. Sections 6-8  $\mu\text{m}$  in thickness were cut with a microtome. The sections were subjected to hematoxylin and eosin staining (HE), silver staining and immunohistochemical staining.

### Silver staining

Silver staining was conducted using a modification of Sevier-Munger method<sup>8</sup>. After deparaffinization, the sections were immersed overnight in 10% silver nitrate aqueous solution. After washing in water, the slides were silver stained in a strongly alkaline ammoniacal silver staining solution containing 30% sodium carbonate (pH 12-14), reduced in 2% formalin solution, and fixed in 5% sodium thiosulfate aqueous solution.

### Immunohistochemistry

Some slides were subjected to immunohistochemical staining

of nerve fibers. The primary antibody used was an antibody against neurofilament protein (68 Kda; CMN) which is a specific neural protein. After staining with 1:200 dilution of the antibody at room temperature overnight, the immunoreactivity in tissue was visualized using the ABC method (ABC Kit; Victor, USA) with the addition of 0.3% Triton X in the reaction mixture. All slides were examined using a light microscope (Olympus BX50).

## Results

The histopathological findings of the premolars of the patient were compared with the normal controls.

### Low power findings

The low power ( $\times 4$ ) micrographs of HE stained section (inset of Figure 5), silver staining (inset of Figure 6) and immunohistochemical staining (inset of Figure 7) showed that the pulp of dental root was almost entirely occluded, with only a part of the pulp cavity remaining visible. The occluded dental pulp appeared lamellar, and a region of fibrosis from the dental pulp to the entire dentin layer as well as a region of deranged dentinal tubules were observed. The remaining pulp cavity was degenerate and atrophic. The anti-neurofilament protein (NFP) antibody stained only the residual dental pulp cavity.

### HE staining

The high power ( $\times 200$ ) section (Figure 5) showed degenerate dental pulp and no odontoblasts. In the dentin, a region adjacent to the dental pulp with no dentinal tubule but rich in fibers running from the dental pulp side to the cementum, a region with deranged dentinal tubules and abundant fibers, and a region with normal arrangement of dentinal tubules presumably primary dentin were observed.

### Silver staining

High power ( $\times 100$ ) silver stained sections (Figure 6) showed degenerate dental pulp and disappearance of odontoblast. In the

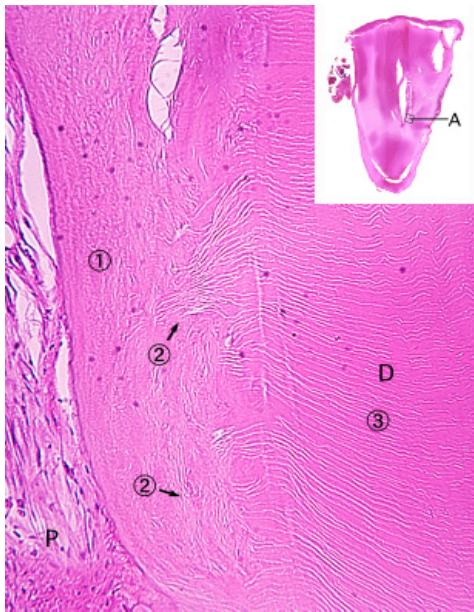


Figure 5. HE staining of a premolar stump, showing high-power magnification of area A shown in the inset. ①: Odontoblast is absent at the dental pulp side, and dentinal tubule is also absent. ②: Region of disrupted alignment of dentinal tubule. ③: Region with apparently normally aligned dentinal tubules. P: pulp, D: dentin.

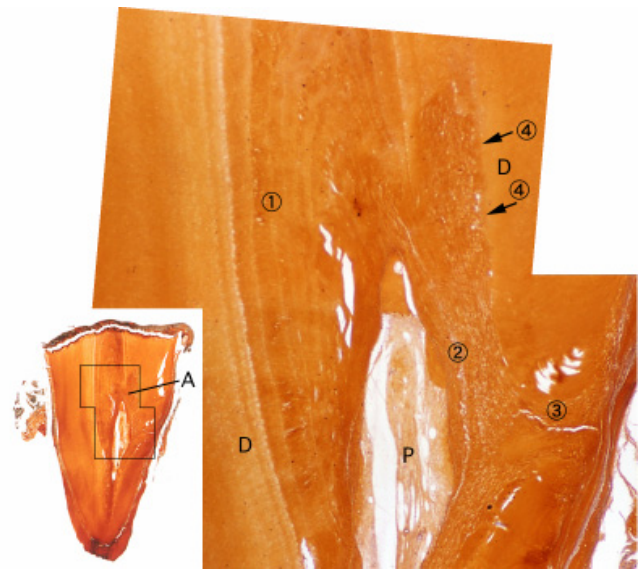


Figure 6. Silver staining of a premolar stump, showing high-power magnification of area A shown in the inset. Degenerate dental pulp and disappearance of odontoblast are noted. ①: Region with lamellar shaped dental tubules in normal arrangement. ②: Fibrotic region with no dentinal tubule. ③: Fibrotic region with dentine in band form. ④: Region with clear border between the primary dentine zone and fibrotic zone. P: pulp, D: dentin.

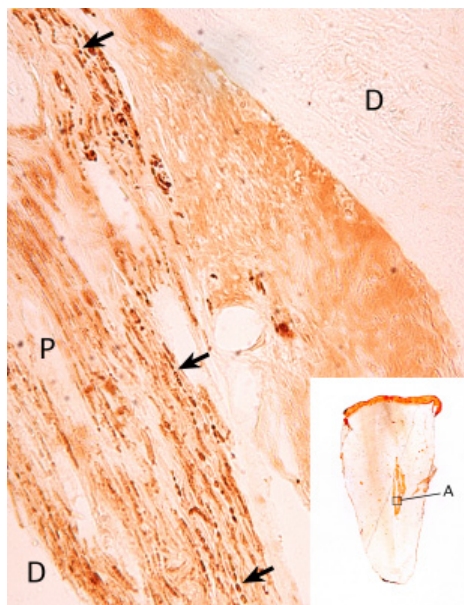


Figure 7: Anti-neurofilament immunostaining of a premolar stump, showing high-power magnification of area A shown in the inset. ( ) bead-like arrangement of nerve fibers. P: pulp, D: dentin.

dental pulp cavity, a region of narrowing with lamellar shaped dentinal tubules in undisturbed arrangement, and a region rich in connective tissue fibers well stained by silver were observed. In the dentine, a region of zonal fibrosis extending from the dental pulp cavity to the entire dentin was observed. In this region, primary dentine had disappeared. There was a clear border between the region of presumed fibrosis and the region of primary dentine.

#### *Anti-NFP antibody immunostaining*

The only region that was positively immunostained was the dental pulp (Figure 7). The positively stained part was almost at the center of the dental pulp. In this region, darkly stained bead-like nerve fibers were observed. No nerve fiber terminals were visible ( $\times 200$ ).

#### **Discussion**

When functional teeth extracted with a diagnosis of dental pulp narrowing are not available as research material, the remaining stumps obtained from the present case are valuable research resources. Especially, dental pulp narrowing was observed in radiographs taken at presentation, indicating that dental pulp narrowing had started over twenty years ago and the process had progressed over time, thus providing evidence that findings in the stumps represent changes of pulp narrowing.

The dental pulp in the samples was narrowed almost along the whole length. The remaining dental pulp was degenerate, probably as a result of receiving abnormal stimulation for a long period of time. In this patient, rheumatoid arthritis was initially diagnosed, although the diagnosis was subsequently changed to SLE. Considering that the patient started taking oral PL from a young age and has continued the treatment to date, the oral PL is speculated to have the strongest impact on the changes in the dental pulp. However, the effect of SLE cannot be ruled out.

The radiograph of the anterior tooth taken at age 25 (Figure 1) already showed that the dental pulp had become obscure and the

patient felt no pain even during tooth grinding (Figure 3). These findings suggest that the same effects observed in the present study had already manifested after the patient had taken PL for 7 or 8 years. These findings are consistent with the report of Näsström<sup>4)</sup> that odontoblasts are affected at the early stage of corticosteroid treatment and calcification of the dental pulp occurs after several years.

The radiograph taken at presentation (Figure 1) showed that dental pulp narrowing occurred in single-rooted teeth such as the anterior teeth, while the multiple-rooted teeth were not affected. This phenomenon is difficult to explain. If the effect was due to PL, then the process should have proceeded simultaneously in all the teeth. Whether there is a difference in blood flow or a difference in odontoblast response between the anterior teeth and molars is unknown. In studies using PL-pretreated rats, Anneroth et al<sup>3)</sup> observed definite bone-like tissues in the incisors, and Näsström et al<sup>9)</sup> demonstrated gradual calcification of molars by tetracycline labeling. Their findings may suggest that the dental pulp changes in the molars may take time to develop.

In the dental pulp cavity, we observed regions containing clear dentinal tubules suggesting involvement of odontoblast and regions containing no dentinal tubules but only fiber component. The mechanism of these findings is unknown. Using a rat model of cavity formation in dentin, Sato<sup>10)</sup> observed that the odontoblasts disappeared at the early stage of cavity formation, followed by regeneration and repair of the odontoblastic layer several days later, probably involving the NFP in the process. In addition, Byers et al<sup>11)</sup> reported increased mRNA expression of nerve growth factor (NGF) during the process of dental pulp repair after dentin cavity formation, while no increase in NGF mRNA was observed during the repair process in pretreatment with dexamethasone. These results suggest the involvement of growth factor in the regeneration of odontoblast and inhibition by dexamethasone. While our present case differs from dentin cavity formation and the results cannot be compared directly, the above findings may suggest that odontoblasts and growth factors may still be involved in the region of lamella formation. We speculate that with gradual narrowing of the dental pulp, deteriorated blood circulation results in a poor nutritional state in the dental pulp cavity; growth factors cannot exhibit their functions and odontoblast regeneration becomes impossible, leading ultimately to repair by fibrous component alone.

Necrosis and regeneration of odontoblast are observed not only during dentin cavity formation, but also in experiments of rats administered anticancer agents. Therefore, it is conceivable that long-term administration of PL, which has complex actions, exerts great effect on odontoblasts. As demonstrated by silver staining, in some parts of the dentin, dentinal tubules had disappeared completely in the entire dentine layer from the dental pulp to the cementum, and were replaced by fibers. The reason for this finding

is unknown. Despite being thickened, the cementum around the whole dental root was in a healthy state. Therefore, the findings observed are likely to be changes originating from the dental pulp and not changes derived from the cementum or periodontal membrane.

The patient did not sense pain in the teeth, which was speculated to be due to some changes occurring in the sensory nerves distributed in the dental pulp. The results of immunostaining with ant-NFP antibody revealed that positively stained nerve fibers did not disappear but were scattered in the narrowed dental pulp. However, instead of the fine branched nerve fibers observed in normal dental pulp<sup>10)</sup>, they were evidently degenerate and assumed a beaded shape. Moreover, the nerve fibers were distributed in the center of the dental pulp and were absent at the boundary between the dental pulp and dentin, suggesting that they were not sensory fibers but fibers from the autonomic nerve system distributing around blood vessels. Further study should be conducted to stain the nerve fibers using specific antibodies to the autonomic nervous system.

## References

1. Robertson A., Lundgren T., Anderson J.O., Dietz I. and Norén J.G. Pulp calcifications in traumatized primary incisors. A morphological and inductive analysis study. *Eur J Oral Sci*, 105: 196-206, 1997
2. Holtgrave E-A., Hopfenmüller W. and Ammar S. Abnormal pulp calcification in primary molars after fluoride supplementation. *ASDC J Dent Child*, 69: 201-206, 2002
3. Anneroth G. and Bloom G.: Structural changes in the incisors of cortisone-treated rats. *J Dent Res*, 45: 229-235, 1966
4. Näsström K. Dentin formation after corticosteroid treatment: A clinical study and experimental study on rats. *Swed Dent J Suppl*, 115: 1-45, 1996
5. Symons A.L. and Symons D.J. Pulpal obliteration related to long-term glucocorticosteroid medication. *Spec Care Dentist*, 14: 103-107, 1994
6. Gold S.I. Root canal calcification associated with prednisone therapy: a case report. *JADA*, 119: 523-525, 1989
7. Shinozuka O., Sekiguchi G, Tamamori Y., Inada M., Yamazaki T. and Ohyama T. Narrowing of the dental pulp cavity in patients undergoing long-term administration of steroids. *Kokubyo Gakkai Zasshi*, 68: 294-299, 2001. Japanese.
8. Sevier A.C. and Munger B.L. A silver method for paraffin sections of neural tissue. *J Neuropath Exp Neurol*, 24: 130-135, 1965
9. Näsström K., Petersson A. and Konrad P. Effect of intravenous administration of corticosteroids on dentin formation in adult rat molar. *Scand J Dent Res*, 97: 301-306, 1989
10. Sato O. Response of pulpal nerve to cavity preparation in rat molar; an immunohistochemical study using neurofilament

Yoshiho Chigono et al.: Dental Pulp Changes by Long-term Corticosteroids

protein (NFP) antiserum. Arch Histol Cytol, 52: 433-446,  
1989

of NGF and P75NGF-receptor by fibroblast of teeth precedes  
sensory nerve sprouting. Growth Factor, 6: 41-52, 1992

11. Byers M.R., Wheeler E.F. and Bothwell M. Altered expression